

Apparent rarity of asymptomatic herpes cervicitis in a woman with intra-uterine contraceptive device

Adeola Fowotade,^{1,2}
 Abu Clement Okolo,³
 Mohammed Mohammed Manga,¹
 Chinenye Gloria Anaedobe,¹
 Ayodeji Akeem Salami,⁴
 Effiong Essien Udo Akang³

¹Medical Microbiology Department, University College Hospital; ²Medical Microbiology Department, College of Medicine, University of Ibadan; ³Pathology Department, College of Medicine, University of Ibadan; ⁴Pathology Department, University College Hospital, Ibadan, Nigeria

Abstract

Infection with genital herpes simplex virus (HSV) remains a common viral sexually transmitted disease, often subclinical and a major worldwide problem of women of reproductive age group. Herpes cervicitis is an unusual presentation of Herpes simplex virus infection in females. The finding of herpes cervicitis on routine pap smear of an asymptomatic woman on Intrauterine contraceptive device still further supports the need for increased awareness on the possibility of Herpes simplex virus infection among women, particularly those on Intrauterine contraceptive device. The index case is a 28 years old Nigerian female who was referred to our Special Treatment Clinic on account of an abnormal pap smear cytology which was in keeping with Herpes cervicitis. There was no history of genital ulcer in this patient; however ELISA for HSV 2 IgM was positive in her. We therefore describe a case of herpes cervicitis in an asymptomatic woman on intrauterine contraceptive device. This case highlights to clinicians the need to be aware of the possibility of this association and to carry out relevant investigations so as to identify and treat these patients appropriately. Therefore, there is a need to put in place adequate public health intervention strategy to prevent genital herpes in women of reproductive age group with a view to preventing the possibility of congenital herpes in subsequent pregnancy.

Introduction

Cervicitis is defined clinically by the presence of either mucopurulent discharge or easily induced bleeding at the endocervical os, more subtle signs include edema of the cervical ectropion (edematous ectopy) and the presence of an elevated number of polymorphonuclear leukocytes, as detected by Gram staining of a smear of endocervical secretions under high-power magnification. Infectious cervicitis might be caused mainly by *Chlamydia trachomatis* and *Neisseria gonorrhoeae*. Other organisms include: herpes simplex virus (HSV), human papillomavirus (HPV) and *Trichomonas vaginalis*.^{1,2}

Although screening for HSV-1 and HSV-2 in the general population is not indicated. HSV serological testing should be considered for people presenting for a sexually transmitted disease evaluation, especially for those people with multiple sexual partners and people with HIV infection.³⁻⁶

Herpes cervicitis becomes important when observed in a woman of reproductive age group because of the risk of neonatal infections resulting from exposure to HSV in the genital tract during delivery. Viral shedding of HSV occurs frequently in infected individuals. HSV is shed asymptotically from multiple anatomical sites and shedding, like exposure, is a significant risk for transmission.⁷

Diseases of the cervix are common in young sexually active women.^{7,8} Non-neoplastic diseases are predominantly inflammatory however there are few publications on the subject compared to neoplastic diseases of the cervix. Common causes include chemical irritations secondary to douching or local trauma produced by pessaries and intrauterine contraceptive devices.⁸

Case Report

A 28-year old female trader referred to the Special Treatment Clinic (STC) of the University College Hospital (UCH) Ibadan, Nigeria with cervical cytology suggestive of herpes simplex cervicitis. This was detected on routine screening for cervical cancer using Pap smear which showed superficial, intermediate, parabasal and endocervical cells. Also seen are binucleated epithelial cells, all of which were suggestive of Herpes simplex cervicitis (Figure 1).

She is para 3-0, 3 alive; last child birth was 4 years ago. All her pregnancies were uneventful and delivered *per vaginam* with no history of delivery of congenitally malformed baby. Though with a desire for future pregnancy, she

Correspondence: Adeola Fowotade, Medical Microbiology Department, College of Medicine, University of Ibadan, Nigeria.
 Tel. 234.70575.19038.
 E-mail: temilabike@yahoo.com

Key words: herpes cervicitis, intra-uterine contraceptive device.

Contributions: AF designed the manuscript and reviewed the clerking of CGA and MMM. She also carried out the ELISA for HSV; CGA and MMM clerked the patient and obtained clinical samples for analysis, they were also involved in manuscript drafting; ACO, AAS and EEUA reviewed the histology slides; EEUA reviewed the final manuscript. All authors contributed to the manuscript and approved the final draft.

Conflict of interests: the authors declare no potential conflict of interests.

Received for publication: 29 August 2013.
 Revision received: Not required.
 Accepted for publication: 14 September 2013.

This work is licensed under a Creative Commons Attribution NonCommercial 3.0 License (CC BY-NC 3.0).

©Copyright A. Fowotade et al., 2013
 Licensee PAGEPress, Italy
 Journal of Public Health in Africa 2013; 4:e14
 doi:10.4081/jphia.2013.e14

currently has an intra-uterine contraceptive device (IUCD) (Copper T 380A) which was placed 2 years ago. Her last menstrual period was on 20th May 2012 (5 days prior to presentation). Last sexual contact was 8 days prior to presentation. She is married in a monogamous family setting. She denied a positive history of multiple sexual partner, however she confirmed that her spouse has other sexual partners (number not revealed).

She had no complaints referring to presence of a sexually transmitted infection at presentation but affirmed to a history of previous recurrent whitish vaginal discharge with no genital malodor. Antibiotics used in treatment could not be remembered. The discharge was observed by her after placement of the IUCD. There was no history of intermenstrual or post-coital bleeding. No dysuria or hematuria.

Physical examination revealed a healthy looking young lady with major findings in the genital system. The external genitalia appeared normal with no blisters, ulcers, warts or other genital/perianal lesions. Speculum examination of the vagina exposed scanty, whitish mucopurulent discharge with no peculiar odor emanating from the cervical os. The ectocervix appeared reddened, edematous, mildly tender on gentle swabbing (no bleed-

ing) with the IUCD string protruding from the endocervix (Figure 2). There was no inguinal lymphadenopathy.

ELISA for herpes simplex virus 1 and 2 IgM screening (Diapro Diagnostics, Milan, Italy) was positive. Retroviral screening done at presentation was non-reactive. *Chlamydia* and *Syphilis* screening were also negative. The endocervical swab taken yielded normal flora. Patient was counseled and treated with oral Acyclovir for 2 weeks. Her spouse was also treated and advised on the use of barrier method. She was re-assessed at the follow up clinic and examination of the cervix showed a marked improvement in the cervical inflammation earlier observed (Figure 3).

Discussion

It has been documented that the use of intrauterine devices may predispose to cervi-

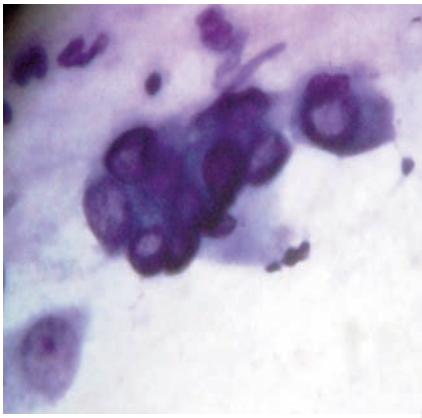


Figure 1. Cytology slide showing multinucleated cells with ground glass nuclear appearance and peripheral margination of chromatin.

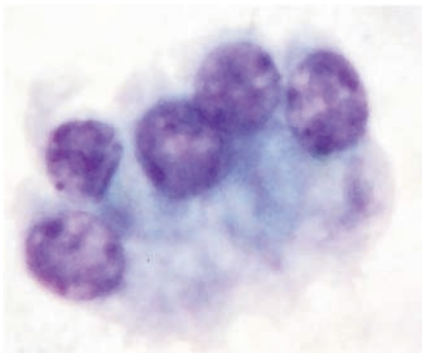


Figure 2. Sections show multinucleated cells with nuclear inclusion bodies and ground glass appearance of the nuclei with peripheral margination of chromatin. There are many binucleated cells also seen.

tis. Infections of the cervix represent an important reservoir for the sexual or perinatal transmission of pathogenic microorganisms and the usual source from which upper genital tract infections develop.

Genital herpes simplex virus infection is common and involves, in the order of frequency, the cervix, vagina, and vulva. The frequency of genital herpes has increased dramatically in the past decades, particularly in teenagers and young women. By the age of 40, about 20% of women are seropositive for antibodies against HSV-2.⁹ HSV cervicitis occurs in 70-90% of primary HSV-2 infections and about 70% of primary HSV-1 infections.¹⁰ However there are no conclusive data on seroprevalence of herpes simplex cervicitis in most parts of the world, this is partly because the prevalence of this disease is very difficult to ascertain by case reporting, as most of the cases are clinically in apparent.^{10,11}

Some of the identified risk factors for Herpes cervicitis were found to be present in our index case. She had an intra uterine device *in situ* for over two years, positive history of an apparently asymptomatic spouse with multiple sexual partners and early age at onset of sexual intercourse.

The typical clinical picture of HSV consists of blistering and ulceration of the cervix.¹² However, in the index case, speculum examination of her cervix revealed a hyperemic and friable cervix, with copious creamy white discharge from the endocervical canal, while ulcers/erosions were absent. This is more in keeping with cervicitis caused by *Trichomonas vaginalis*, *Chlamydia trachomatis* or *Neisseria gonorrhoea* which are more common causes of infectious cervicitis and as such are usually considered first as differentials. Hence many patients go undiagnosed and untreated for

Herpes cervicitis. However, culture of the endocervical discharge in this patient yielded normal flora, she was also negative for *Chlamydia*, *Trichomonas vaginalis* and *Gonorrhoea*.

The diagnosis of HSV-2 in our patient was done using enzyme-linked immunosorbent assay. The sensitivity of these tests for detection of HSV-2 antibody vary from 80% to 98%, while the specificity of these assay is above 96%.¹² We did not have facilities for cell culture which is gold standard for diagnosis of herpes simplex virus infection with a higher specificity of above 99%. We also do not have facility for polymerase chain reaction, which is highly sensitive, even more than viral culture, and highly specific as well.³ To the best of our knowledge, this is the first case of herpes cervicitis to be reported from this centre. Even though Oni *et al.* had earlier reported herpes simplex infection among attendees of our Special treatment clinic⁵. It has been documented that prompt initiation of anti herpetic treatment shortens the duration of the disease, and may reduce rate of recurrence and virus shedding by inhibiting replication.¹¹ Our patient also showed a dramatic improvement after two weeks on oral Acyclovir.

Genital HSV infection has been associated with persistent inflammatory cervical smears in a study done; the increased cervical cancer risk was associated with a history of chronic cervicitis.¹² In another study focusing on gynecological infections other than HPV as risk determinants of subsequent cervical neoplasia, association with cervical HSV infection gave the highest and statistically most significant increase in risk.¹³ Genital HSV-2 infection facilitates acquisition of HIV infection. Studies have shown that prevalent HSV-2 infection is associated with a 2-3 fold increased risk of acquiring HIV infection, while incident HSV-2 infection is associated with an even higher risk of acquiring HIV infection. Genital HSV-2 infection is thought to facilitate transmission of HIV infection from persons who are co-infected with both viruses. Without typical clinical symptoms of HSV infection, the patient is generally not screened for HSV infection thus putting the women at risk.

This case was a young woman in the reproductive age group who desired to have more children. This incidental finding and treatment of this index case has probably contributed to preventing the complications of genital HSV infection *viz a viz* the possibility of sexual transmission of the disease, as well as perinatal transmission with emergence of congenital malformation in infants of infected mothers. This case also illustrates the importance of effective routine Pap smear for sexually active women.

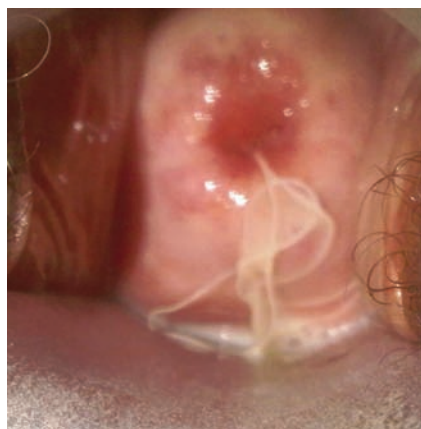

Figure 3. A Slide showing the edematous and reddened cervix.

Conclusions

In conclusion, cervicitis increases the risk of poor pregnancy outcome, predicts upper genital tract disease, and is associated with increased shedding of HIV-1 from the cervix in the absence of chlamydial and gonococcal infection. Hence determining the etiology of this condition should be considered a priority. Herpes cervicitis often presents as an asymptomatic condition that may be detected incidentally. Therefore it should be considered as a differential diagnosis of cervicitis among sexually active women particularly those with intrauterine device.

References

1. Marrazoi, JM, Martin, DH. Management of women with cervicitis. *Clin Infect Dis* 2012;54:102-10
2. Centers for Disease Control and Prevention. Chlamydia screening among sexually active young females enrollees of health plans - United States, 2000-2007. *MMWR Weekly* 2009;58:362-5.
3. Adelson ME, Feola M, Trama J, et al. Simultaneous detection of herpes simplex virus types 1 and 2 by real time PCR and pyrosequencing. *J Clin Virol* 2005;33:225-34.
4. Looker KJ, Garrett GP, Schmid GP. An estimate of the global prevalence and incidence of HSV-2. *Bull WHO* 2008;86:737-816.
5. Oni AA, Ekweozor CC, Bakare RA. Genital Herpes simplex virus infection in females in Ibadan, Nigeria. *W Afr J Med* 1996;15:107-10
6. Workowski KA, Berman S. Center for Disease control and Prevention. Sexually transmitted disease guidelines. *MMWR* 2010;59:1-10.
7. Sacks SL, Griffiths PD, Corey L, et al. HSV shedding. *Antivir Res* 2004;63:19-26.
8. Xu F, Schllinger JA, Sternberg MR. Seroprevalence and coinfection with herpes simplex virus type 1 and type 2 in the United States, 1988-1994. *J Infect Dis* 2002;185:1019.
9. CDC STD prevention. STD Curriculum for Clinical Educators. Genital Herpes simplex virus (HSV) Module. Available from: <http://www.cdc.gov/std/treatment/> Accessed: 4 June 2012.
10. Brugha R, Keersmaekers K, Renton A, Meheus A. Genital herpes infection: a review. *Int J Epidemiol* 1997;26:698.
11. Anneli U, Elve R. Atypical genital herpes: report of five cases. *Scand J Infect Dis* 2004;36:37-9.
12. [No authors listed]. Practical sexual health problems in genito-urinary medicine-three case reports. *Sexual Health Matters* 2002;3. Available from: <http://www.sexualhealthmatters.com>
13. Jones C. Cervical cancer: is herpes simplex virus type II a cofactor? *Clin Microbiol* 1995;8:549-56.